

PennHIP Report

Referring Veterinarian: Dr Rachael Campbell	Clinic Name: Binford Pet Wellness Clinic
Email: binford@petwellnessclinics.com	Clinic Address: 5640 E. 71st Street Indianapolis, IN 46220
	Phone: (317) 578-1298
	Fax: (317) 288-0923

Patient Information

Client: Vestal, Kerdra	Tattoo Num:
Patient Name: Noble Vestals Ima Major Babe	Patient ID: Baby
Reg. Name: Noble Vestal's Ima Major Babe	Registration Num: ALAA-103580
PennHIP Num: 170119	Microchip Num: 913000320481856
Species: Canine	Breed: MIXED BREED
Date of Birth: 28 May 2021	Age: 10 months
Sex: Female	Weight: 24.9 lbs/11.3 kgs
Date of Study: 04 Mar 2022	Date Submitted: 04 Mar 2022
Date of Report: 08 Mar 2022	

Findings

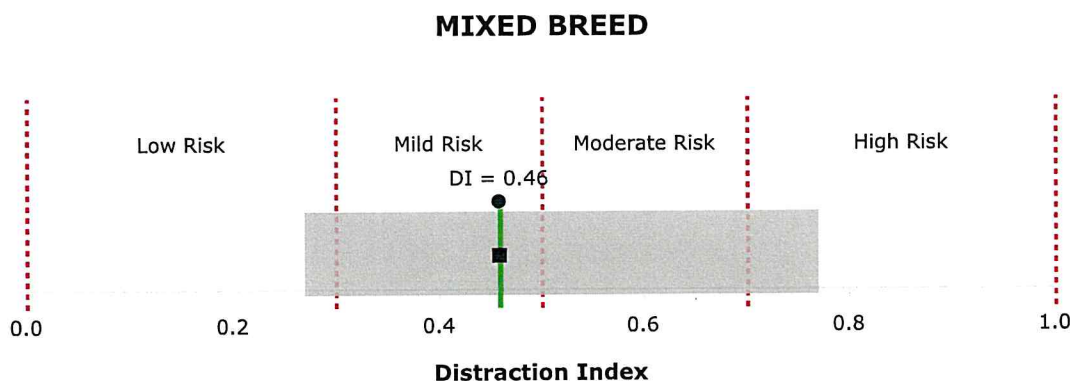
Distraction Index (DI): Right DI = 0.46, Left DI = 0.38.
 Osteoarthritis (OA): **No radiographic evidence of OA for either hip.**
 Cavitation/Other Findings: No cavitation present.

Interpretation

Distraction Index (DI): The laxity ranking is based on the hip with the greater laxity (larger DI). In this case the DI used is 0.46.

OA Risk Category: The DI is between 0.31 and 0.49. This patient is at mild risk for hip OA.

Distraction Index Chart:



BREED STATISTICS: This interpretation is based on a cross-section of 11456 canine patients of the MIXED BREED breed in the AIS PennHIP database. The gray strip represents the central 90% range of DIs (0.27 - 0.77) for the breed. The breed average DI is 0.46 (solid square). The patient DI is the solid circle (0.46).

SUMMARY: The degree of laxity (DI = 0.46) falls within the central 90% range of DIs for the breed. This amount of hip laxity places the hip at a mild risk to develop hip OA. **No radiographic evidence of OA for either hip.**